Ultrasonographic intraoperative monitoring and follow-up of Kaposi's sarcoma nodules under treatment with intralesional vincristine

Giovanni Genovese, Gianluca Nazzaro, Athanasia Tourlaki, Emanuela Passoni, Emilio Berti, Lucia Brambilla

Dermatology Unit, IRCCS Fondazione Cà Granda Ospedale Maggiore Policlinico, Milan, Italy
Department of Physiopathology and Transplantation, Università degli Studi di Milano, MILAN, Italy

Introduction

Kaposi's sarcoma (KS) is a rare, low-grade vascular tumor associated with human herpesvirus type 8 (HHV8) infection. Histologically, KS lesions are characterized by clusters of spindle-shaped cells and prominent microvasculature with thin-walled and dilated blood vessels. Clinical suspect of KS due to the presence of blue-red to purple macules, nodules or plaques needs to be confirmed by histopathological assessment. Although skin ultrasonography (US) has been recently used as diagnostic tool in a variety of dermatologic diseases, to date limited literature exists on the use of US in mucocutaneous KS. Moreover, contradictory ultrasonographic aspects of the morphological structure of KS lesions are described in the literature. Intralesional chemotherapy with vinblastine or vincristine represents an effective and safe palliative treatment for KS nodules on the skin or on mucous membranes and may be a valid support to systemic chemotherapy for single nodular lesions causing functional impairment. Vincristine is a natural alkaloid that exerts antiblastic effects irreversibly binding to microtubules and spindle proteins and interfering with the mitotic cycle and may be used alone or in combination with other cytotoxic drugs as a systemic chemotherapeutic regimen in KS. In a previous study on 151 patients, we have demonstrated that intralesional vincristine is an effective and safe treatment for nodular lesions in classic KS. Herein, we evaluated cases of cutaneous classic KS treated with intralesional vincristine by means of ultrasonography both intraoperatively and during the follow-up visits, in order to further demonstrate and to monitor the efficacy of the treatment.

Methods

This study was conducted at the Dermatology Unit of the University of Milan from January 2017 to June 2018. All patients selected for the study had histologically proven classic KS presenting with cutaneous nodules, were negative for human immunodeficiency virus (HIV) and were at least 18 years old. Staging was performed according to the system proposed by Brambilla et al in 2003. Intralesional chemotherapy of skin KS lesions was performed using insulin syringes with 6 mm × 31 G needle containing vincristine. Each nodule was treated by the same investigator (A.T.) utilizing an amount of vincristine which was considered adequate for the size of the lesion and inclining the needle by 45°. Ultrasonographic assessment was carried out with a multifrequency (15.0-18.0-MHz) linear array transducer (ARIETTA V70, Hitachi Medical Systems®, Zug, Switzerland). After the acquisition of the intraoperative imaging, each patient was re-evaluated by means of US after 1 and 3 months. Partial response was defined as reduction of more than 50% of the volume of the nodule and reduction of the vascular signal at the color Doppler examination. Complete response was defined as resolution of KS nodule associated with the absence of vascular signal.

Results

Five patients with cutaneous classic KS nodules were enrolled in the present study. Each of them had at least one KS nodule. A total of 6 nodules were treated with vincristine and evaluated by means of US after 1 and 3 months. The patients were predominantly males (n = 4; 80%). The median age at the time of diagnosis was 78 years (range: 70-85 years). The median KS duration was of 12.5 years (range 2-20 years). Based on the staging system of Brambilla et al, 2 patients were at stage IB and 3 patients were at stage IIB. All KS nodules appeared at B-mode as oval or round hypoechoic structures with well-defined edges and homogeneous content (Figure 1A), located in the dermal-epidermal layer, and in two cases also in the subcutaneous tissue. Color Doppler examination revealed intralesional vascularization, more prominent in the deepest pole of the nodule (Figure 1B).

We gave the name of "diamond ring-like" sign to this sonographic finding due to the morphology of the nodule resembling a ring and a prominent vessel at the deepest pole mimicking a diamond. Spectral analysis showed biphasic arterial flow (Figure 1C). At month 1 after vincristine injection, a new ultrasound assessment showed complete response in 4 (66.7%) nodules. This was confirmed by the absence of the prominent vessel at the deepest pole, suggesting this as a distinctive sign of response to therapy. In the wo remaining nodules, we observed a partial response, with color Doppler showing intralesional vascularization and microvascular spot in the prominent vessel at the deepest pole. These two lesions were treated with a new infiltration of vincristine. After 3 months from the first vincristine injection, all lesions in complete response at month 1 maintained the clinical remission, while the 2 nodules retreated with intralesional vincristine at month 1 were completely cleared. Color Doppler examination confirmed the absence of vascularization in all lesions.

Discussion

US may have a role in guiding the surgical treatment of selected cases of KS presenting with voluminous nodules, providing information about the nodule size and its extension toward the underlying tissues. However, in general, the aim of skin sonographic examination should be to monitor the disease activity and to assess the clinical response to therapy. In fact, color Doppler imaging can be useful in assessing the response to therapy, since it allows to monitor a progressive reduction in vascularization of the nodule and a subsequent loss of vascularization in the completely regressed nodule (Fig. 2). This study showed the presence of a prominent vessel at the level of the deepest pole of the nodule. From a theoretical point of view, US could be a useful method to identify the prominent vessel of the KS nodule during the intralesional chemotherapy infiltration, in order to selectively inject the chemotherapeutic agent in that point. In practice, this procedure is quite time-consuming, cannot be performed by a single operator and requires experienced physicians in skin ultrasound. It is, however, a useful procedure in the follow-up of lesions under treatment. In fact, a progressive reduction in the calibre of the vessels of the deepest pole of the nodule was observed during the follow-up, and this ultrasonographic finding was corroborated by clinical evaluations. In conclusion, US seems to be an affordable and reliable tool in assessing clinical response to intralesional vincristine therapy for cutaneous KS nodules.

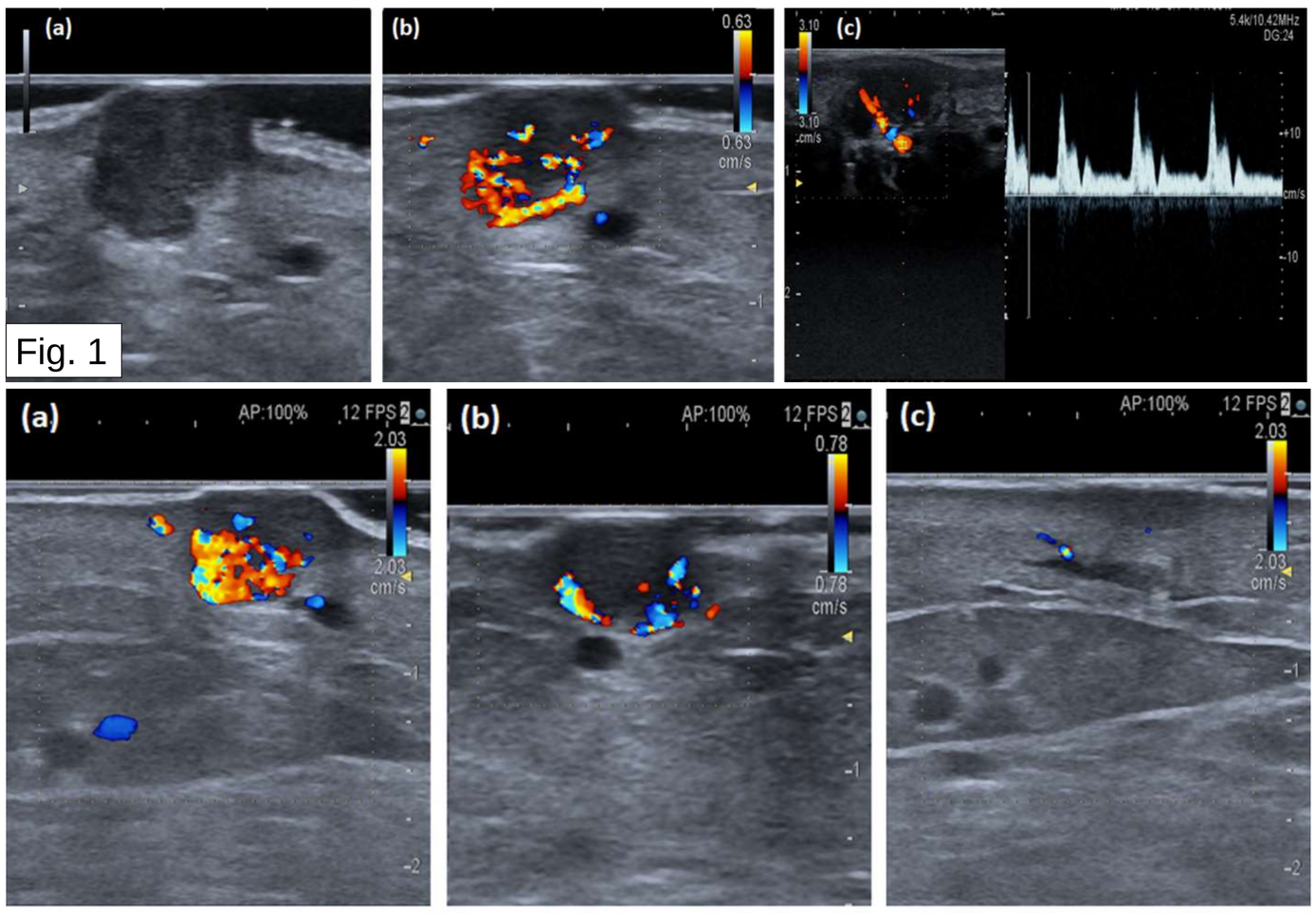

Fig. 1

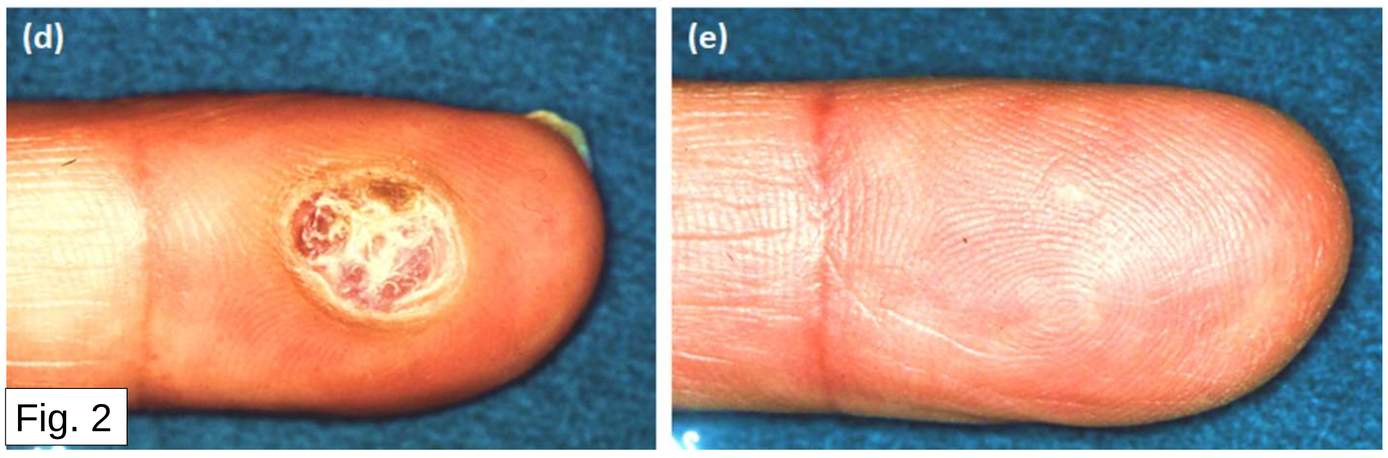

Fig. 2

Contact details: giov.genov@gmail.com; luciabrambilla1@virgilio.it; gianluca.nazzaro@gmail.com